# 6th WSES Congress 2019

**Title**: Sub-Capsular Appendicectomy in Complicated Appendicitis: safer and easier than standard appendicectomy

**Authors:** Professor Zaheer ud Din Qureshi, Professor Irfan ud Din Khattak

**Affiliations:** Ayub Medical College and Ayub Teaching Hospital, Abbottabad

**Topic:** Emergency Abdominal Surgery

**Background:** Appendicectomy may be difficult in complicated appendicitis, including appendicular mass, recurrent appendicitis, or adhesions and may entail morbidity and mortality. Sub-Capsular Appendicectomy (Mucosectomy) may be a better alternative.

**Aim:** Objective of the present study was to compare subcapsular appendicectomy with standard appendicectomy in complicated appendicitis, in terms of ease of procedure, safety, and complications.

**Methods:** In this prospective study; patients presenting with complicated appendicitis were allocated to Group 1 (standard appendicectomy) or Group 2 (subcapsular appendicectomy). First patient was allocated to group on ballot; next patient to the other group. Operative time, technical difficulties during surgery including intra- and post-operative complications and length of hospital stay besides other variables were recorded on *pro forma*, and regularly followed. At 1 year, clinical examinations ultrasound scans were performed to assess outcome of the distal sero-muscular layers left behind.
In SubCapsular Appendicectomy, base of the Appendix was ligated, cut, artery forceps applied at the distal cut surface, and serosa slit circumferentially distal to this forceps. Mucosa was wriggled out by pulling on forceps, leaving distal serosa and muscular coat behind.

**Results:** Out of 260 patients, 130 underwent standard and 130 Sub-Capsular Appendicectomy. Standard Appendicectomy patients required extension of incision more frequently, had longer operating times, presented more intraoperative technical difficulties resulting in more frequent surrounding structure damage and hemorrhage. Wound infection rates were comparable. Chronic abdominal pain was seen more often in standard appendicectomy group (15 % (n=20) vs 6% in subcapsular appendicectomy (n=8)). Clinical examinations and US scans at year 1 were clear.

**Discussion:** Sub-Capsular Appendicectomy is easier, takes less time to complete and is safer. Leaving infected muscular and serosal layers behind do not produce any complications. Chronic RIF pain is seen less frequently in subcapsular appendicectomy.

*Figure 1 Appendix Burried in Adhesion. Tip may be difficult to deliver*

*Figure 2. Base of the Appendix may be identified, ligated and cut withoutdisturbing the rest of the Appendixw*

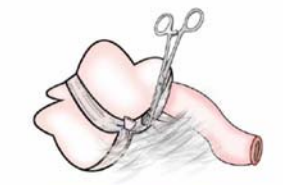

*Figure 3. Circumferential cut in sero-muscular layers allows pull on the mucosa*

*Figure 4. Mucosa may be wriggled out leaving the sero-muscular layer burried within the adhesions or mass*