6th WSES Congress 2019

Title: TENSION PNEUMOPERITONEUM SECONDARY TO BAROTRAUMA

Authors: Gil-Olarte Márquez, MA; García-Santos, EP; Menchen-Trujillo, B; García-Schiever, JG; Viton-Herrero, R; Martín-Fernández, J.

Affiliations: Department of General Surgery. General University Hospital of Ciudad Real, Spain.

Topic: Abdominal emergency surgery

Background: Tension pneumoperitoneum is an infrequent complication. It is defined as the increase of gas in the peritoneal cavity, which may cause a true abdominal compartment syndrome. It is characterized by a serious deterioration of the respiratory and cardiocirculatory function of the patient due to compression of large vessels and the diaphragm, which decreases the pulmonary compliance. In this situation, the first therapeutic measure must be the emergency decompression of the abdominal cavity

Methods and results: Clinical case.
A 75-year-old female patient was admitted in the emergency ward with hypercapnia secondary to acute respiratory failure. Due to the deterioration of her clinical status, she was transferred to the Intensive Care Unit. After the failure of non-invasive ventilation, an orotracheal intubation was performed and mechanical ventilation started. Immediately afterwards, great abdominal distension, and hemodynamic and respiratory compromise developed. Pneumoperitoneum was diagnosed in a radiological control.
In the operating room, immediate decompression was performed by midline laparotomy. Findings during surgery were a damaged gastric serous surface, with a perforation in the lesser curvature. Primary closure of the defect was performed.

Discussion: Pneumoperitoneum is usually due to the perforation of hollow organs, with the consequent exit of gastric or intestinal air to the peritoneal cavity. In the rest of cases, we speak of asymptomatic, benign or idiopathic pneumoperitoneum. When no clear cause for the pneumoperitoneum is found in the medical history, mechanical ventilation is considered the most frequent cause.
Most of the tension pneumoperitoneum cases described in the literature occur in patients undergoing mechanical ventilation due to different respiratory pathologies. Severe deterioration follows, both from the hemodynamic and respiratory point of view. The severity of these symptoms requires, in many cases, immediate abdominal decompression to lower the intra-abdominal pressure, and therefore improve the patient's hemodynamic status.

WSES
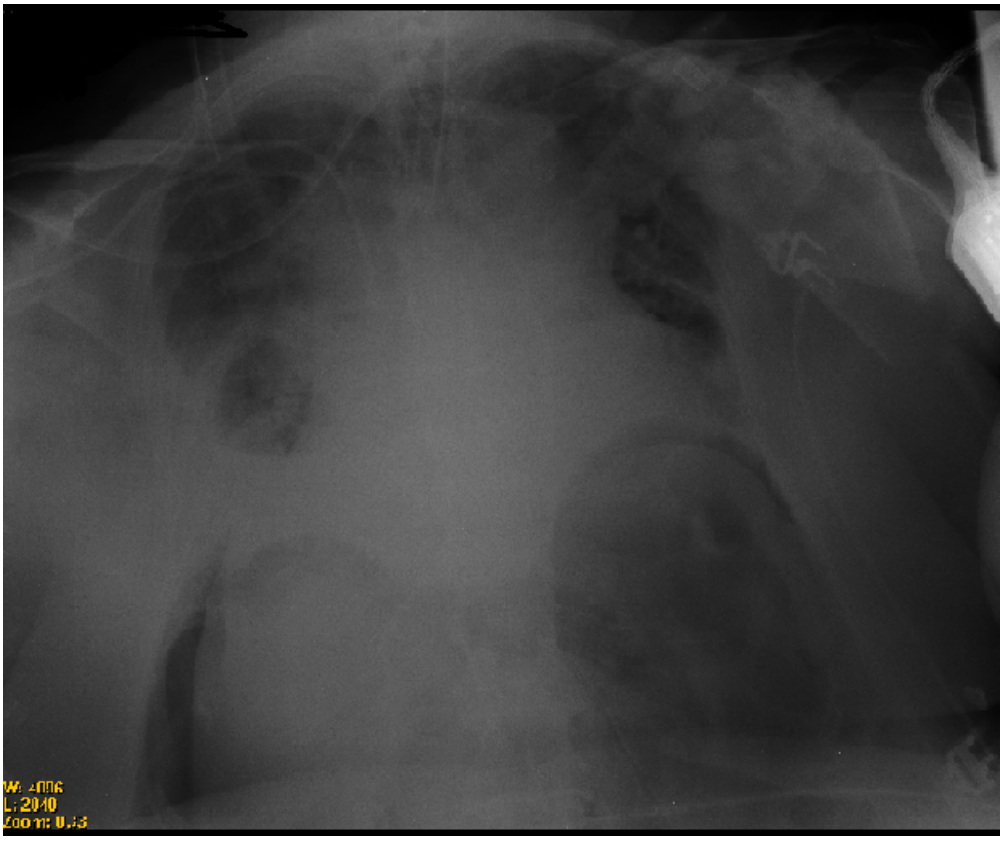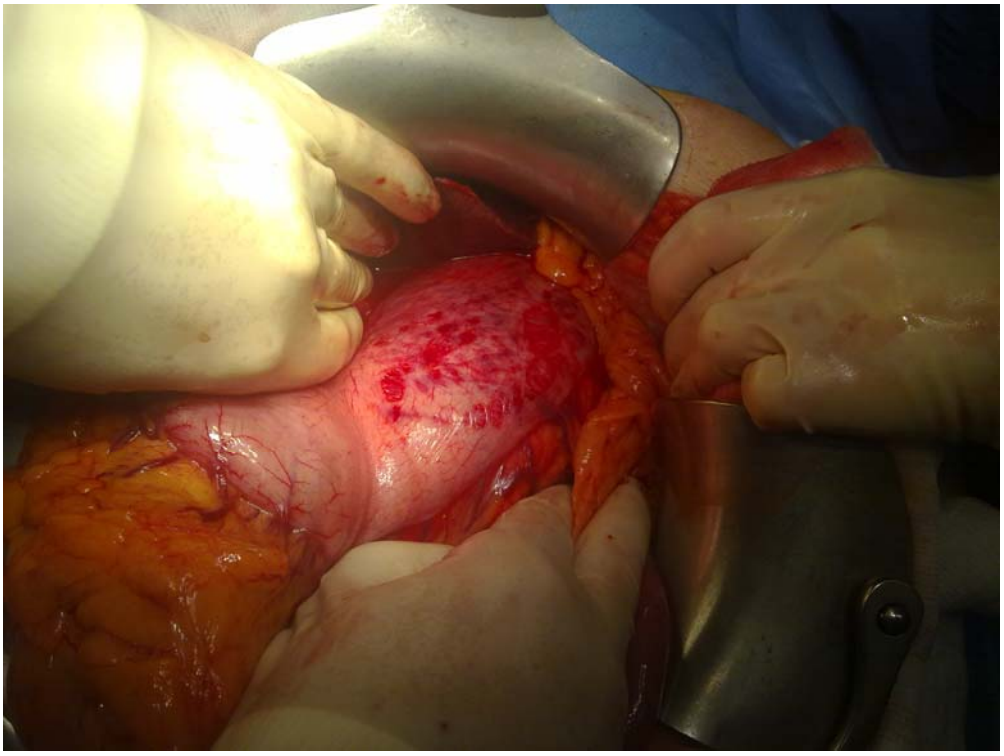
Radboudumc
university medical center